MORPHOLOGICAL CHANGES IN THE BRONCHI IN CHILDREN AGED 4-5 YEARS

Sadikova Zumrad Shavkatovna – professor
Bakieva Muhabbat Tursunkulovna – assistant
Tashkent state medical university (Tashkent, Uzbekistan)

Abstract: *The scientific significance of the results of the study in the article the dynamics of morphometric development of trachea in the respiratory system among children of the first childhood, the bronx tree in the period from birth to a month consists of tissues in which all layers of the tracheal wall of children did not find a good evolution, the wall of the, the transformation of the private plate from a multicellular unformed state to a fibrous-structured connective tissue, from a flat and swollen appearance to a round and dense appearance of taut rings, the histological structure of the lungs and bronchi of various calibers, the assessment of morphometric changes of epetilium, connective, muscle tissue complications was explained by the creation of theoretical foundations for assessing age-binding properties.*

Key words: *Bronchial floors, morphological changes, control group, children, observation group.*

4-5 YOSHLI BOLALARDA BRONXLARNING MORFOLOGIK O‘ZGARISHLARI

Sadikova Zumrad Shavkatovna – professor
Bakiyeva Muhabbat Tursunkulovna – assistent
Tashkent davlat tibbiyot universiteti (Tashkent, Uzbekistan)

Annotatsiya: *Maqolada tadqiqot natijalarining birinchi bolalik davrida bo‘lgan bolalar orasida nafas olish tizimidagi traxea, bronx daraxti morfometrik rivojlanish dinamikasi tug‘ilgandan bir oygacha bo‘lgan muddatda bolalarning traxeya devorining barcha qatlamlari yaxshi takomil topmagan to‘qimalardan iboratligi, o‘pka bo‘laklari bosh bronxlari devori birinchi bolalik davrda varonkasimon shakldan silindrsimon shaklga, qoplovchi epiteliysi ko‘p qatorli shakli, burmali holatdan bir qavatli silliq tuzilish, xususiy plastinkasi ko‘p hujayrali shakllanmagan holatdan tolali tuzilmali shakllangan biriktiruvchi to‘qimaga, tog‘ay halqalari yassi va shishli ko‘rinishdan dumaloq va zich ko‘rinishga aylanish, o‘pka va turli kalibrdagi bronxlarini gistologik tuzilishini, morfometrik o‘zgarishini baholashda epetiliy, biriktiruvchi, fibroz-tog‘ay, mushak to‘qimalarining asoratlanishini yoshga bog‘lik xususiyatlari baholashning nazariy asoslari yaratilganligi bilan izohlangan.*

Kalit so‘zlar: *Bronxlarning qavatlari, morfologik o‘zgarishlar, nazorat guruh, bolalar, kuzatuv guruh.*

МОРФОЛОГИЧЕСКИЕ ИЗМЕНЕНИЯ БРОНХОВ У ДЕТЕЙ 4-5 ЛЕТ

Садикова Зумруд Шавкатовна – профессор
Бакиева Мухаббат Турсункуловна – ассистент
Ташкентский государственный медицинский университет (Ташкент, Узбекистан)

Резюме: *В статье представлены результаты исследования трахея в дыхательной системе у детей первого детского возраста, морфометрическая динамика развития бронхового дерева в период от рождения до месяца все слои стенки трахеи детей состоят из недоразвитых тканей, фрагменты легких стенка главного бронха в первом детском возрасте имеет форму от варонкообразной до цилиндрической, покровный эпителий имеет многорядную форму, однослойная гладкая структура из складчатого состояния., переход от многоклеточного неформального состояния с частными пластинками к сформированной соединительной ткани с фиброзной структурой объясняется тем, что созданы теоретические основы оценки возрастных особенностей осложнений эпителиальной, соединительной, фиброзно-точечной, мышечной ткани при оценке гистологического строения, морфометрических изменений легких и бронхов различного калибра.*

Ключевые слова: *Складки бронхов, морфологические изменения, контрольная группа, дети, наблюдательная группа.*

Introduction. According to statistics, up to 40% of children brought to the pulmonology department by ambulance are patients with bronchoobstructive syndrome (7,8,9,10,11,12,13,14). Despite the general clinical signs characterized by choking attacks, stretching of breathing, cough with low sputum, sometimes noisy and flattering breathing with the involvement of the respiratory auxiliary muscles, bronchoobstructive syndrome causes heterogeneous diseases (15,16,17,18,19,20,21,22). The most common cause of the development of the syndrome is bronchial asthma, obstructive bronchitis and defects in the development of the lungs and bronchi. The main importance in the pathogenesis of bronchial obstruction in respiratory infections is due to the heterogeneous activity of the bronchi in the de-

scription of inflammation, bronchospasm and mucosal hypersecretion, swelling of the mucous membrane of the bronchi, its inflammatory infiltration (1,2,3,4,5,6).

The purpose of the study: Analysis of morphological changes in the bronchi in children aged 4-5 years.

Research materials and methods: In order to achieve the goal set before us and to complete the tasks, autopsical materials were obtained from the remains of 45 first-child children in the postnatal ontogenetic stage of the pulmonary bronchi without diseases of the respiratory system. Examination at the Republican Center for patalogical Anatomy 2023-2025 The first adopted in the i-quarter was carried on the corpse of children in childhood. Children who died under the influence of various factors, but whose respiratory system did not change, were studied in children's corpses who died as a result of mainly heart defects and other causes that did not have diseases in the pulmonary bronchial tract. The causes of death and underlying disease have been identified in forensic medicine and pathological anatomy conclusions. The examination material was obtained from the following parts of the lungs: i.e.: trachea, right and left lungs were studied by opening the outer and inner bronchi from the lateral bronchi to the terminal bronchi.

Results of the study: While separately analyzing the morphometric indicators of the layers of the Bronx wall, it was found that the one-layer epithelium covering the surface of the mucous membrane is a relatively low structure in shape at one month, that is, due to its prismatic shape, its thickness is also small, quantitatively accounting for 5.0±1.08% of the thickness of all layers.While separately analyzing the morphometric indicators of the layers of the Bronx wall, it was found that the one-layer epithelium covering the surface of the mucous membrane is a relatively low structure in shape at one month, that is, due to its prismatic shape, its thickness is also small, quantitatively accounting for 5.0±1.08% of the thickness of all layers. It was observed that by the age of 4 years, due to an increase in the size of the single-layer prismatic epithelium, its thickness also slightly increased, averaging 6.3±1.2%. Similar dynamics were observed in the later months of the early postnatal period, with 7.4±1.3% at age 5, and 8.2±1.4% at 12 months. From this quantitative data, to the general conclusion, it was found that the bronchial wall covering epithelium thickened slightly less than twice during the early postnatal period from one month to the 12th month. It is known that it was observed that the connective tissue private plate of the mucous membrane of the bronx wall has an unformed structure at the age of one month of infancy, its intermediate substance is dominated by nardon and edema processes, its thickness is 15.5±1.8% of the thickness of all layers of the bronx wall. In the following months of the early postnatal period, it was found that cells and fibrous structures in the unformed connective tissue in the mucosal private plate were relatively Evolute, resulting in a decrease in the tumor process in the intermediate, with its relative thickness at 3 years - 14.8±1.7%, age 4 -13.2±1.7%, age 5 - 11.8±1.6%. The smooth muscle layer of the bronchial wall was conversely observed to begin at one month in the early postnatal period and become more regularly thickened in its later months as a result of both the number and size increases of muscle cells, from 10.5±1.5% in one month to 4% by the age of 5, and reached 14.6±1.5%. In the early postnatal period of children, one of the structures in the respiratory tract wall that performs another important function is the mucous gland structures that synthesize a mucus substance.

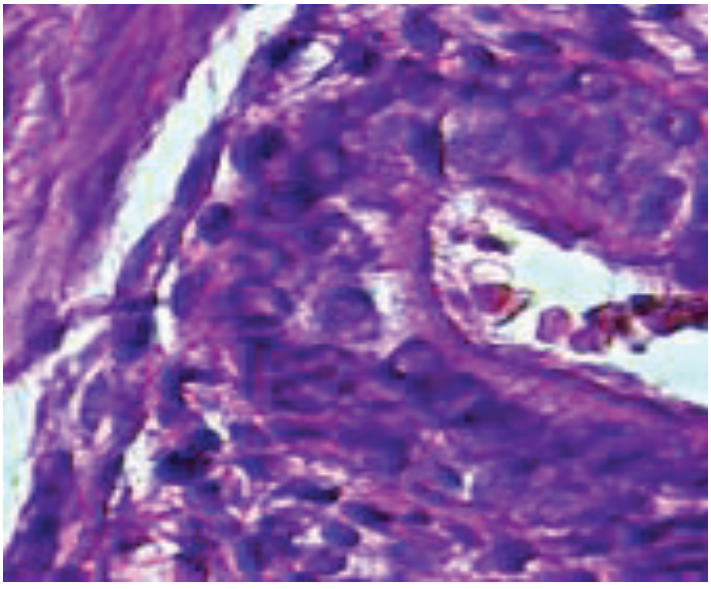

4-year-old children's trachea. Mucous membrane twisted, covering epithelium multi-row stained with hematoxylin-eosin. Magnified image at 10x40

Our research results show that morphologically, as well as morphometrically, these glands increase and increase in the dynamics of the early postnatal period, as well as the area occupied.n the early postnatal period of children, one of the structures in the respiratory tract wall that performs another important function is the mucous gland structures that synthesize a mucus substance. Our research results show that morphologically, as well as morphometrically, these glands increase and increase in the dynamics of the early postnatal period, as well as the area occupied. At the age of 4 years, it was found that the bronx wall occupied a third of the area of all its layers, that is, 31.0±2.3% of the space. It was found that the next period of examination, 32.4±2.3% at age 3, 34.6±2.3% at age 4, and 36.4±2.4% at age 5. Hence, overall it was observed that the area expanded by 5.5% by the end of the early postnatal period.It was found that the next period of examination, 32.4±2.3% at age 3, 34.6±2.3% at age 4, and 36.4±2.4% at age 5. Hence, overall it was observed that the area expand.

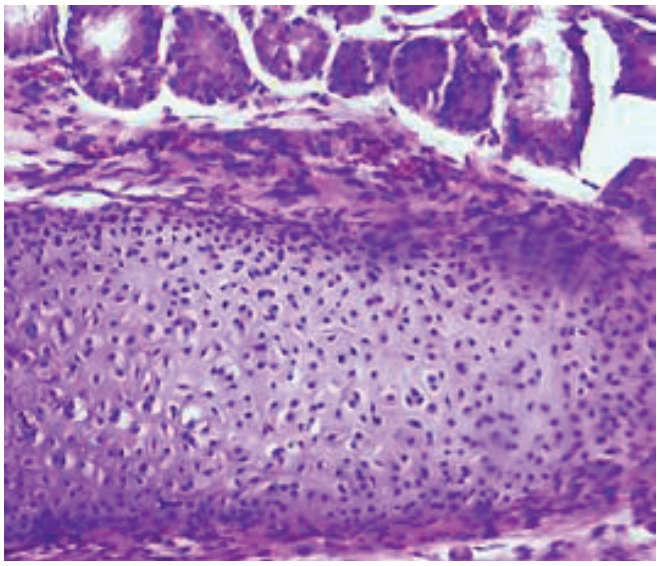

5 years of age. Trachea. The tracheal ring is thickened the number of glands has increased stained with hematoxylin-eosin. Magnified image at 10x40

At the age of 5 years, it was observed that the layers of the trachea, the wall of the throat, grew rapidly. It was found that the tissue of the lower platelets of trachea became denser, the lower platelet material increased and the cells decreased, the chondrocytes contained in it formed at a higher level than in previous periods, decreased compared to the intermediate chondroid substance, the connective tissue Tufts around it became denser.t the age of 5 years, it was observed that the layers of the trachea, the wall of the throat, grew rapidly. It was found that the tissue of the lower platelets of trachea became denser, the lower platelet material increased and the cells decreased, the chondrocytes contained in it formed at a higher level than in previous periods, decreased compared to the intermediate chondroid substance, the connective tissue Tufts around it became denser. The submucosal layer was found to be expanded, thinned, and to contain an increased number of connective tissue fibers and cells compared to the previous period. The mucous membrane is relatively thick, with an epithelial single-layer structure that covers its surface. The mucous membrane of the trachea was preserved thin, thin, the glandular cells in them, well developed in comparison with the previous period, were slightly swollen and enlarged, the covering epithelium was observed to contain a large number of smooth epithelia with a surface relative to the ciliated epithelium.he mucous membrane is relatively thick, with an epithelial single-layer structure that covers its surface. The mucous membrane of the trachea was preserved thin, thin, the glandular cells in them, well developed.

Conclusion: 1.Deep layers of the private plate were found to contain smooth muscle cells consisting of a single tuft located in a circular direction. It is followed by smooth muscle cell Tufts, in the deep layers of which a row is located. The thickness of the Tufts varied, and it was observed that fine connective tissue interstititium occupied a place between them.

2.Under the muscle Tufts are the private glands of the trachea, the difference from previous periods is that the glandular yachts are relatively large, the cells are obese and the apical part is in a vacuolated state. Mountain peoples are surrounded by a veil of connective tissue in a dense state. The intermediate in the tissue of the tuber was found to be a dark ink stain, relatively low in cells, with some in a vacuolated state.

3.When a histochemical method was used to detect connective tissue Tufts in the tracheal wall, it was found that connective tissue fibers proliferated and densely located around the private plate, the mucous membrane and the people.

REFERENCES

1. Akhmedova S.M., Nortaeva N.A., Nortaev A.B. Morphological changes in the teeth of adolescent children with hypotireosis // Collection of materials of the scientific and practical conference with international participation, dedicated to the 100th anniversary of the Tashkent Medical Academy, "100 years of the Tashkent Medical Academy – the era of great achievements and discoveries". Tashkent, 2022 -P. 199-200
2. Nortaeva N.A., Akhmedova S.M., Nortaev A.B. Morphological changes in the teeth adolescent children with hypotireosis // Problems of biology and medicine. - Samarkhand, 2022. - P 270. ISSN 218 2-5674, https://doi.org/10.38096/2181-5674.2022
3. Nortaeva N.A., Nortaev A.B. Morphological changes in teeth against the background of experimental hypothyroidism // Topical issues of modern scientific research. -Dushanbe 2022.-P 168.
4. Nortaeva N.A., NortaevA.B. Morphological changes in the tooth in experimental hypothyroidism // Issues of innovative development of science, education and technology. - Andijan, 2022.-P 273-275
5. Nortaeva N.A., Nortaev A.B., Akhmedova S.M. To study the morphological changes in the tooth against the background of experimental hypothyroidism // Current problems of microbiology. - Tashkent, 2022 -P. 148-152
6. Nortaeva N.A. Morphological changes in teeth as a result of malnutrition in preschool children // Proceedings of the conference dedicated to the 95th anniversary of academician, morphologist, scientist Komiljon Zufarov. - Tashkent, 2021 -P. 34-36
7. Nortaeva N.A., Akhmedova S.M. Morphological changes in the dental in experimental hypotireosis // Collection of materials of the scientific and practical conference of young scientists with international participation, dedicated to the 100 th anniversary of the Tashkent Medical Academy, «innovative approaches in medicine». Tashkent, 2022 -P. 51
8. Nortaeva N.A., Akhmedova S.M., Nortaev A.B. Anthropometric indicators of the maxillofacial system in school–aged children with hypothyroidism // Modern scientific research topical issues, achievements and innovations. Current scientific issues, current affairs, achievements and innovations. Penza, 2023 –P. 153. ISBN 978-5-00173-707-0
9. Nortaeva N.A., Akhmedova S. M., Nortaev A.B., Rajabov B.M. Changes in the face-jaw system of experimental hypothyroidism // Texas Journal of Medical Science https://zienjournals.com 2023 –P. 61-64 ISSN NO: 2770-2936
10. Nortaeva N., Akhmedova S., Berdiev O., Anthropometric dimensions of the maxillofacial system in children with hypothyroidism aged 8-16 year // Journal of Medicine and Innovations www.tsdi.uz 2023 –P. 230-235 ISSN 2181-1873
11. Nortaeva N.A.,Akhmedova S.M.,Nortaev A.B, Effects of hypothyroidism on the maxillofacial system // Uzbek journal of case reports 2023 –P.126, Том 3. https://doi.org/10.55620/ujcr.3.sp.2023
12. Usmanov R.Dj., Gulmanov I.D., Nortaev A.B. Development and prevalence of periodontal diseases in workers working with chemical paints // 100 years of the Tashkent Medical Academy – the era of great achievements and discoveries – 2022. P-244.
13. Saidov A.A. Periodontal disease and its prevention in workers of the textile industry // Monograph-2020. 134 p.
14. Volozhin A.I., Filatova E.S., Petrovich Y.A. and others. Evaluation of the state of the periodontal by the chemical composition of the environment of the oral cavity // Dentistry. -2000. №1- P. 13-16.
15. Nortaev A.B., Rajabov B.M., Berdiev O.V. Oral inflammation in light industry workers // Texas Journal of Medical Science ISSN NO: 2770-2936. - 2023. P-84-86. https://zienjournals.com
16. Nortaev A.B.,Usmanov R.Dj.,Nortaeva N.A. Periodontal disease and its complications in 21-30-year-old chemical paint workers // Journal of medicine and innovations ISSN 2181-1873 2023.P-215-220 www.tsdi.uz
17. Nortaev A.B.,Usmanov R.Dj., Berdiev O.V. Use of cefixime in the treatment of periodontal disease in industrial employees // Farmaecutil journal №3, 2023 P. 77-80 UDK: 616.314.18-002.4-885:615. 331:323.329
18. Nortaev A.B.,Usmanov R.Dj.,Ibragimova Sh.A. Severe Consequences of the Development of Periodontal Disease in the Example of Employees Working in Light Industrial Plants // Texas Journal of Medical Science ISSN NO: 2770-2936 https://zienjournals.com Date of Publication:06-05-2023 P- 110-113
19. Nortaev A.B., Usmanov R.Dj., Berdiev O.V. Periodontal disease and its complications in 21-30-year-old chemical paint workers // Journal of oral medicine and craniofacial research Samarkhand - 2023. P.-21
20. Nortaev A.B., Akhmedova S.M., Usmonov R.Dj. Periodontal disease and its development in the case of employees of chemical shops // Uzbek journal of case reports Part 3. Samarkhand - 2023. P.-130
21. Nortaev A.B., Usmanov R.Dj., Rajabov B.M. The level of periodontal disease in 20-28-year-old textile industry workers // 77th International Scientific and Practical Conference "Achievements of Fundamental, Applied Medicine and Pharmacy". Samarkhand - 2023. P.-525
22. Nortaev A.B.,Usmanov R.Dj.,Gulmanov I.Dj. Etiology of the development of periodontal disease in workers of the manufacturing industry // "Current aspects of the pathogenesis of diseases caused by environmental factors" Materials of international scientific and practical conference Tashkent – 2023. P-11-12