UDC: 616.314-089.843:311.2-615.849.19

EFFECT OF LASER PATTERNED MICROCOAGULATION ON OUTCOMES OF CONNECTIVE TISSUE GRAFT AT DENTAL IMPLANT SITES

Shomurodov Kakhramon Erkinovich – D.M.Sc., professor
Mirkhusanova Rano Sergey kizi – Ph.D., doctoral student
Tashkent State Medical University (Tashkent, Uzbekistan)

Abstract. *The study aimed to evaluate volumetric outcomes, angiogenic biomarkers and microcirculation parameters following laser patterned microcoagulation (LPM) sessions on CTG-grafted sites. 25 patients with soft tissue dehiscence underwent STG using CTG. Two weeks after STG, LPM sessions were performed on one side of the jaw, while the contralateral side healed without laser application (split-mouth study). LPM was conducted using a 1550 nm diode laser. The analysis of outcomes was based on the KMW and MT gains, microcirculation parameters, and angiogenic biomarkers release in gingival crevicular fluid (GCF) of two adjacent natural teeth. Measurements showed that KMW and MT gain were significantly higher at LPM sites. LPM improved microcirculation and venous outflow, decreased peripheral flow resistance, and normalized vascular tonus. Vascular endothelial growth factor and platelet-derived growth factor-BB values were significantly higher in GCF from the LPM sites. LPM has a positive effect on outcomes of soft tissue augmentation by promoting neocollagenesis, cell proliferation and enhancing graft revascularization.*

Keywords: *diode laser, soft tissue augmentation, microcirculation, biomarker, dental implantation.*

ВЛИЯНИЕ НЕАБЛЯЦИОННОГО ЛАЗЕРНОГО ФОТОТЕРМОЛИЗА НА РЕЗУЛЬТАТЫ АУГМЕНТАЦИИ СОЕДИНИТЕЛЬНОТКАННОГО ТРАНСПЛАНТАТА В ОБЛАСТИ ДЕНТАЛЬНЫХ ИМПЛАНТАТОВ

Шомуродов Кахрамон Эркинович – д.м.н., профессор
Мирхусанова Рано Сергей кизи – Ph.D., докторант
Ташкентский государственный медицинский университет (Ташкент, Узбекистан)

Аннотация. *Целью исследования была оценка объема мягких тканей, содержания биомаркеров ангиогенеза и параметров микроциркуляции после сеансов неабляционного лазерного фототермолиза (НЛФ) на участках с СТТ. 25 пациентам с недостаточным объёмом мягких тканей была проведена трансплантация СТТ. Через две недели были проведены сеансы НЛФ на одной стороне челюсти, в то время как противоположная сторона заживала без применения лазера (исследование "split-mouth"). НЛФ проводилась с помощью диодного лазера с длиной волны 1550 нм. Анализ результатов основывался на увеличении ширины КД и ТСО, параметрах микроциркуляции и содержании биомаркеров ангиогенеза в десневой жидкости двух соседних зубов. Результаты показали, что увеличение ширины КД и ТСО было значительно выше на участках НЛФ. Наблюдалось улучшение микроциркуляции и венозного оттока, снижение периферического сопротивления и нормализация сосудистого тонуса. Значения фактора роста эндотелия сосудов и фактора роста тромбоцитов-ВВ были значительно выше в десневой жидкости, полученных из участков НЛФ. Обнаружено положительное влияние НЛФ на результаты аугментации мягких тканей, способствуя неоколлагенезу, пролиферации клеток и улучшая реваскуляризацию трансплантата.*

Ключевые слова: *диодный лазер, аугментация мягких тканей, микроциркуляция, биомаркер, дентальная имплантация.*

DENTAL IMPLANTATLAR SOHASIDA BIRIKTIRUVCHI TO‘QIMALI TRANSPLANTAT AUGMENTATSIYASI NATIJALARIGA NOABLYATSION LAZER FOTOTERMOLIZINING TA’SIRI

Shomurodov Qahramon Erkinovich – t.f.d., professor
Mirxusanova Ra’no Sergey qizi – Ph.D., doktorant
Toshkent davlat tibbiyot universiteti (Toshkent, O‘zbekiston)

Annotatsiya. *Tadqiqotning maqsadi biriktiruvchi to‘qima transplantati (BTT) augmentatsiyasi bajarilgan hududlarda noablyatsion lazerli fototermoliz (NLF) muolajalaridan so‘ng yumshoq to`qimalar hajmi, angiogenez biomarkerlari miqdori va mikrotsirkulyatsiya parametrlarini baholashdan iborat. Yumshoq to‘qimalar hajmi yetarli bo‘lmagan 25 nafar bemorda BTT augmentatsiyasi o‘tkazildi. Ikki haftadan so‘ng, jag‘ning bir tomonida NLF muolajalari o‘tkazildi, qarama-qarshi tomon esa bitdi (“split-mouth” tadqiqot dizayni). NLF to‘lqin uzunligi 1550 nm bo‘lgan diodli lazer yordamida amalga oshirildi. Natijalar tahlili ikki qo‘shni tishlarning milk suyuqligida KM kengligi va ShQQning oshishi, mikrotsirkulyatsiya parametrlari va angiogenez biomarkerlari miqdoriga asoslangan. Natijalar shuni ko‘rsatdiki, KM kengligi va ShQQning oshishi NLF bajarilgan hududlarda sezilarli darajada yuqori bo‘ldi. Mikrotsirkulyatsiya va venoz oqimning yaxshilanishi, periferik qarshilikning pasayishi va qon tomir tonusining me’yorlashuvi kuzatildi. Qon tomir endoteliysi o‘sish omili va trombotsitlar o‘sish omili-BB qiymatlari NLF bajarilgan hududlardan olingan milk suyuqligida sezilarli darajada yuqori bo‘ldi. Neokollagenez, hujayralar proliferatsiyasi va transplantat revaskulyarizatsiyasini yaxshilash orqali yumshoq to‘qimalar augmentatsiyasi natijalariga NLFning ijobiy ta’siri aniqlandi.*

Kalit so‘zlar: *diodli lazer, yumshoq to‘qimalar augmentatsiyasi, mikrotsirkulyatsiya, biomarker, dental implantatsiya.*

Introduction. The importance of peri-implant soft tissue parameters as a factor of successful dental implantation has been reflected in the number of research and systematic reviews during the last two decades. Some studies emphasized that implants with insufficient keratinized mucosa width (KMW) and thin mucosa are more exposed to plaque accumulation, a higher level of marginal bone loss, and soft tissue recession [1]. Stefanini et al. found that non-augmented sites may be prone to soft-tissue apical margin shift, while peri-implant grafted sites maintain stable soft tissue margin and marginal bone levels [2]. According to Zucchelli et al., an apically positioned flap (APF) in combination with a connective tissue graft (CTG) is considered the technique of choice for posterior sites with a lack of keratinized mucosa [3,4].

Adequate tissue perfusion is crucial for a timely and optimal healing process after surgical interventions, including soft tissue grafting. The lack of masticatory load on the edentulous site leads to a reduction of blood supply. A surgical intervention may enhance microcirculation for a short period of time. Inadequate blood supply sets back graft revascularization and the overall healing process. According to Tavelli et al., early tissue perfusion outcomes are correlated with the clinical and volumetric outcomes of soft tissue grafting a year after surgery [5].

Laser patterned microcoagulation (LPM) is based on creating isolated micro-columns of thermal wounds surrounded by normal tissue. Thermal damage induces the release of heat shock proteins that contribute to faster healing of injured areas by stimulating neocollagenesis and elastic tissue formation. Previous studies found a positive effect of LPM on local hemodynamics and peri-implant soft tissue parameters [6,7]. However, there is only one published research on the effect of LPM on wound healing process and volumetric outcomes of soft tissue grafting without detailed discussion of the obtained results. The authors based their study only on evaluation of tissue perfusion and KMW gain.

Thus, all these facts determine the need for more detailed research. This study aimed to evaluate volumetric outcomes, expression of local angiogenic biomarkers, and parameters of hemodynamics following LPM sessions on CTG-grafted implant sites.

Material and Methods. The prospective clinical study with a split-mouth design was approved by Institutional Ethical Committee and performed at the Department of Maxillofacial Surgery from January to October 2025 in accordance with the WMA Declaration of Helsinki of 1984.

Subjects satisfying the following inclusion criteria were consecutively enrolled in the clinical trial from the patient flow: systemically healthy adults with bilateral isolated edentulous spaces (between two natural teeth) in the posterior maxilla/mandible with soft tissue dehiscence (KMW < 2mm); signed informed consent. The exclusion criteria were age ≤18 and ≥75 years, complete edentulism; scars, strands, ulcers or tumors on peri-implant mucosa; poor oral hygiene; heavy smoking (> 10 cigarettes/day); history of previous bone and/or soft tissue augmentation at the implant site; acute inflammation of the peri-implant zone (mucositis, periimplantitis); missing LPM session(s) or follow-ups.

Prior to implant installation, participants underwent treatment of soft tissue dehiscences using palatal CTG. The interventions were carried out under local anesthesia using ARTINIBSA 4% with epinephrine 1:100.000 (INIBSA, Barcelona, Spain) and appropriate techniques (infiltration, block techniques). Following the split-mouth study design, LPM sessions were performed on one side of the jaw, while the site on the contralateral side healed without laser application. Left-right allocation of the laser exposure was specified via “a double coin toss” method two weeks after STG. The microcoagulation columns were created using a 1550 nm diode laser

DIOMAX (KLS MartinGroup, Tuttlingen, Germany) with power parameters of 20 W, 1 Hz, and 120 ms pulse. The procedure was performed under local application anesthesia with Xilonibsa Spray 10% (INIBSA, Barcelona, Spain). The density of microcoagulation columns was 4-8 spots on 1 mm^2. The treatment included four LPM sessions with a two-week interval.

KMW gain was calculated as the difference between KMW at two weeks following the last LPM session and KMW at baseline measured with a periodontal probe after applying Schiller's Iodine Solution. MT was assessed ultrasonographically on E-CUBE 9 Diamond (Alpinion medical systems, Seoul, South Korea) equipped with an intraoral sensor IO3-12 (3~12 MHz). MT gain was obtained as the difference between MT at two weeks following the last LPM session and MT at baseline.

Local hemodynamics were evaluated using Minimax-Doppler-K (Minimax, Saint Petersburg, Russia) by two independent blinded specialists. Measurements were performed prior to the intervention and two weeks after the last LPM session.

The study assessed the expression of angiogenesis biomarkers in gingival crevicular fluid (GCF) of two adjacent natural teeth 14, 30, and 90 days after soft tissue augmentation (before the 1st and 2nd LPM sessions, and 2 weeks following the last one, respectively). GCF was sampled using sterile PerioPaper strips (Oralflow Inc., New York, USA), which were inserted into the crevice for 30 seconds. In case of blood contamination paper strips were excluded from the analysis. Then the paper strips were put into microfuge tubes with 300 μL phosphate-buffered saline and protease inhibitor (Sigma-Aldrich, Saint Louis, USA). The samples were delivered for biochemical analysis to the University Central Laboratory. The levels of angiogenin (ANG), fibroblasts growth factor-2 (FGF-2), tissue inhibitor of metalloproteinases-2 (TIMP-2), vascular endothelial growth factor (VEGF), and platelet-derived growth factor-BB (PDGF-BB) were obtained using the ELISA microplate reader Infinite F50 (TECAN, Grodig, Austria) and ELISA kits Quantikine (R&D Systems, Minneapolis, USA).

OriginPro 8.6 software (OriginLab Corporation, Northampton, USA) was used for statistical analysis and data plotting. A $p < 0.05$ was considered statistically significant.

Results. 52 subjects were assessed for eligibility. Initially, 28 patients were enrolled in the study and underwent soft tissue augmentation. However, three participants were excluded due to missing LPM session. Thus, a total of 25 patients were analyzed. The patients were 38-52 years old, with a mean age of 45.8 ± 3.4 years. Characteristics of the patients and baseline data are presented in Table 1.

Table 1.

Participants characteristics and baseline parameters

Parameters		Values
Sex	Male, n (%)	15 (60%)
	Female, n (%)	10 (40%)
Location	Maxilla, n (%)	11 (44%)
	Mandible, n (%)	14 (56%)
Sites (n=50)	Premolars, n (%)	20 (40%)
	Molars, n (%)	30 (60%)
KMW (mean ± SD, mm)		1.79 ± 0.88
MT (mean ± SD, mm)		1.43 ± 0.28

Notes: KMW, keratinized mucosa width; MT, mucosal thickness; SD, standard deviation.

Table 2.

Clinical outcomes at baseline and 3 months (mean ± SD, mm)

Parameters	KMW		MT	
	CTG	CTG + LPM	CTG	CTG + LPM
Baseline	1.82 ± 0.86	1.76 ± 0.98	1.44 ± 0.24	1.38 ± 0.22
3 months	2.61 ± 1.25	3.72 ± 1.12	2.28 ± 0.15	2.72 ± 0.20
Gain	0.79 ± 0.18	1.96 ± 0.14*	0.84 ± 0.16	1.34 ± 0.18*

Notes: KMW, keratinized mucosa width; MT, mucosal thickness; SD, standard deviation.

All patients showed a painless post-op period, LPM procedures, and intervals between sessions. No sign of inflammation or other types of complications (necrosis, bleeding, scar formation, etc.) was noticed during appointment visits. Cold pulp testing (CPT) did not identify any pathological changes in the responsiveness of the neighboring teeth. KMW and MT increased in both test and control sites. KMW and MT gain were significantly higher at sites that underwent LPM sessions after soft tissue augmentation ($p < 0.05$) – 1.96 ± 0.14 mm versus 0.79 ± 0.18 mm and 1.34 ± 0.18 mm versus 0.84 ± 0.16 mm, respectively. However, there were no statistically significant differences in final KMW and MT values (Table 2).

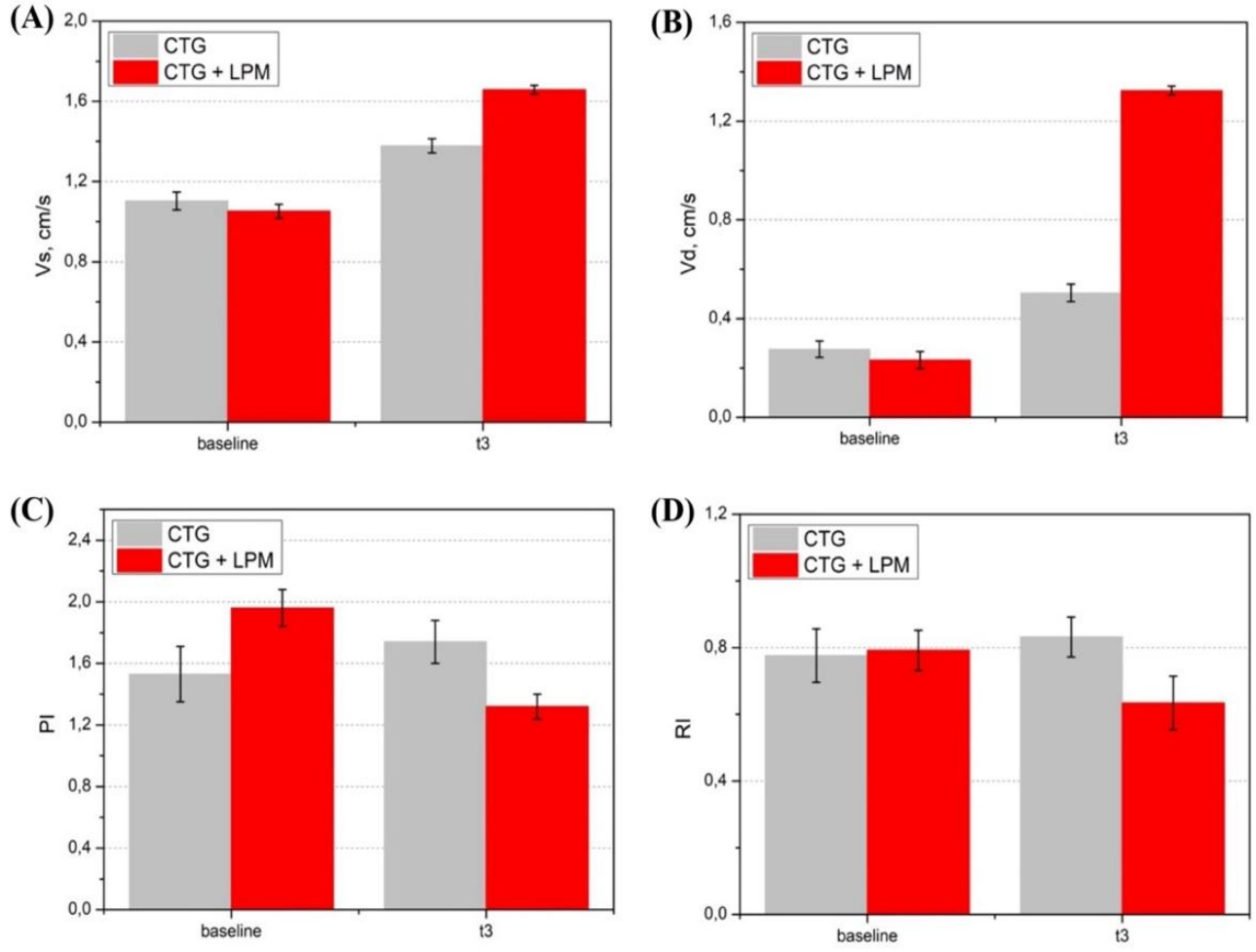

Fig. 1. **Microcirculation parameters at baseline and 2 weeks after the last LPM (t3). (A) Vs, peak systolic velocity, cm/s; (B) Vd, peak diastolic velocity, cm/s; (C) PI, pulsatility (Gosling) index; (D) RI, resistive (Pourcelot) index**

Initial local hemodynamics parameters indicated a reduction of blood supply as a consequence of the insufficient masticatory load [7, 8]. Higher levels of Gosling (PI) and Pourcelot (RI) indexes indicated high peripheral flow resistance, complicated venous outflow, and decreased vascular elasticity. A minor enhancement was noticed in the microcirculation parameters of the control sites 90 days after soft tissue augmentation. Peak systolic and diastolic velocities increased and reached 1.378 ± 0.07 cm/s and 0.504 ± 0.05 cm/s, respectively. More noticeable positive changes in blood supply were observed at the LPM sites. Gosling (PI) and Pourcelot (RI) indexes decreased by 32.7% and 19.9%, respectively. Consequently, it pointed to improved venous outflow due to decreased peripheral flow resistance and normalized vascular tonus (Fig. 1).

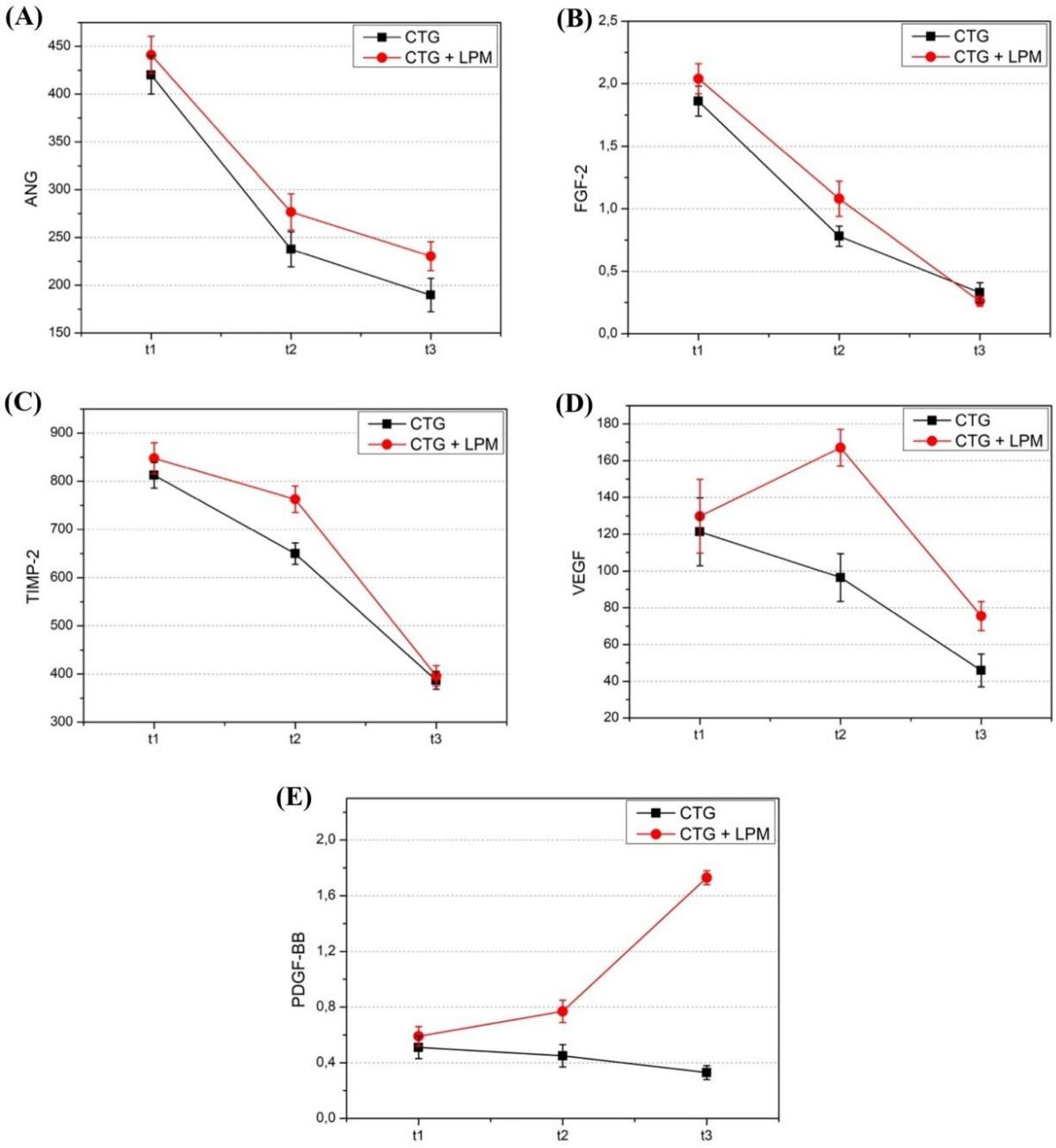

Fig. 2. **Biomarkers levels in pg/ml. (A) angiogenin, (B) FGF-2, (C) TIMP-2, (D) VEGF, (E) PDGF-BB. t1, 14 days after STA (before the 1st LPM session); t2, 30 days after STA (before the 2nd LPM session); t3, 90 days after STA (2 weeks after the last LPM session)**

Identical biomarker values were observed two weeks after soft tissue augmentation. Nevertheless, statistically significant differences were revealed in the expression of TIMP-2, VEGF, and PDGF-BB between control and test sites after the application of LPM. While the control sites demonstrated a decrease in all biomarkers' levels, VEGF and PDGF-BB release in the test sites increased till the second LPM session. Higher levels of TIMP-2, VEGF, and PDGF-BB were found in GCF samples obtained from the LPM sites before the second session (t2) – 762.59 ± 22.16 pg/ml, 167.09 ± 20.04 pg/ml, and 0.69 ± 0.08 pg/ml, respectively. Two weeks after the last LPM session, statistically significant differences were revealed only in values of VEGF and PDGF-BB. In addition, PDGF-BB release maintained the upward trend and amounted to 1.73 ± 0.06 pg/ml in GCF collected from the test sites (Fig. 2).

Discussion. LPM is based on creating isolated micro-columns of thermal wounds surrounded by normal tissue. Activated heat shock proteins promote neocollagenesis and elastic tissue formation,

which result in faster healing and re-epithelization. Yaremenko et al. assumed that LPM sessions are effective in minor mucogingival defects. The authors detected increase of KMW values in 60% of cases, with an average gain of 0.9 mm [9]. Our previous study demonstrated the positive impact of laser application on peri-implant soft tissue. Laser exposure caused the increasing of KMW values and the thickening of gingiva at implant sites [7]. Similar results were obtained in the current study, KMW and MT gains were significantly higher at sites that underwent LPM sessions after soft tissue augmentation ($p < 0.05$). Average KMW and MT gain were 1.96 ± 0.14 mm and 1.34 ± 0.18 mm, respectively.

Adequate tissue perfusion is crucial for a prompt and optimal healing process following surgical procedures, including soft tissue grafting (STG). The lack of masticatory load on the edentulous site leads to the reduction of blood flow and complicated venous outflow due to the deterioration of vascular elasticity [8,10]. Laser exposure enhances vascularization and blood supply due to the formation of new thin-walled vessels related to active fibroblasts proliferation. LPM promotes angiogenesis and the growth of connective tissue with a rich capillary network. Consequently, the procedure has a positive impact on blood supply, tissue nutrition, and the healing process [7,11,12]. In our study, LPM sessions had the same effect on microcirculation parameters. Pourcelot and Gosling indexes pointed to improved blood supply and venous outflow due to decreased peripheral flow resistance and normalized vascular tonus. Hence, laser exposure promotes quicker graft revascularization and has a positive impact on wound healing process.

Several studies have assessed the expression of biomarkers in GCF to evaluate the wound healing process after different soft tissue augmentation procedures. A number of biomarkers were marked as a potential non-invasive diagnostic tool to evaluate early wound healing process after STG at implant sites [13-15]. ANG, PDGF-BB, and VEGF are known as potent angiogenic biomarkers accelerating graft revascularization and promoting reparative processes. According to Tavelli et al., VEGF is directly associated with MT gain, and TIMP-2 correlates with the total soft tissue coverage at implant sites. However, the authors noted that increased values of TIMP-2 at later time points may denote persistent inflammation and delayed healing at the grafted sites, which may lead to a contraction of the soft tissue with a consequent apical shift of the mucosal margin [16]. FGF-2 is a potent angiogenic factor and promotes fibroblast proliferation, cell migration, and wound closure. Tavelli et al. observed that the expression of FGF-2 achieved the highest level 3 days after STG, then decreased to baseline values [15]. In our study, VEGF and PDGF-BB values were significantly higher in GCF obtained from the sites that underwent LPM. Other evaluated biomarkers (ANG, FGF-2, and TIMP-2) had higher release only after the first session, followed by matching with the values of the control sites. VEGF values correlated with MT gain and microcirculation parameters. Higher values of VEGF expression after LPM indicate a greater vascularization of the graft and contribute to enhancing the outcomes of soft tissue augmentation. It is also important to highlight the elevated expression of PDGF-BB in GCF from test sites after LPM. This factor promotes cell proliferation, the growth and migration of fibroblasts, and formation of new blood vessels. A high PDGF-BB expression indicates intensified healing, neocollagenesis, and vascularization processes after laser exposure.

Among the limitations of this study, the relatively short follow-up period should be mentioned. It would be beneficial to evaluate the stability of final soft tissue values after a certain period of functional load. Moreover, the promising results of this clinical trial can be the basis for new studies on LPM application after different soft tissue grafting techniques.

Conclusion. Laser patterned microcoagulation has a positive effect on healing and results of soft tissue augmentation by promoting neocollagenesis, cell proliferation and enhancing local blood supply, graft revascularization. Further prospective studies with a larger sample size should be carried out to evaluate long-term outcomes and determine the stability of soft tissue parameters.

REFERENCES

1. Roccuzzo A, Imber JC, Stähli A, Romandini M, Sculean A, Salvi GE, et al. Role of Keratinized Mucosa on the Risk of Peri-Implant Diseases and Soft Tissue Dehiscence in the Posterior Mandible – A 20-Year Prospective Cohort Study. J Periodontal Res. Published online July 21, 2025.

2. Stefanini M, Barootchi S, Sangiorgi M, Pispero A., Grusovin M. G., Mancini L, et al. Do soft tissue augmentation techniques provide stable and favorable peri-implant conditions in the medium and long term? A systematic review. Clin Oral Implants Res. 2023;34(S26):28-42.

3. Zucchelli G, Tavelli L, McGuire MK, Rasperini G, Feinberg SE, Wang HL, et al. Autogenous soft tissue grafting for periodontal and peri-implant plastic surgical reconstruction. J Periodontol. 2020; 91(1):9-16.

4. Tavelli L, Barootchi S, Majzoub J, Chan HL, Giannobile WV, Wang HL, et al. Ultrasonographic tissue perfusion analysis at implant and palatal donor sites following soft tissue augmentation: A clinical pilot study. J Clin Periodontol. 2021;48(4):602-14.

5. Tavelli L, Kripfgans OD, Chan H-L, Vera Rodriguez M, Sabri H, Mancini L, et al. Doppler ultrasonographic evaluation of tissue revascularization following connective tissue graft at implant sites. J Clin Periodontol. 2025;52(1):68-79.

6. Yaremenko AI, Zernitskiy AYu, Zernitskaya EA, Stolyarova AI. Laser modification of soft tissues in the peri-implant zone. Institute of Dentistry. 2020;87:33-5.

7. Shomurodov K, Mirkhusanova R, Mikhalchenko D. Effect of Laser Patterned Microcoagulation on Keratinized Mucosa Width and Gingival Thickness Around Dental Implants. Malays J Med Health Sci. 2024;20(6):195-200.

8. Shomurodov K, Mirkhusanova R. Application of the soft tissue expanding technique before guided bone regeneration of an atrophic alveolar ridge. JUMMEC. 2023;26(1):170-8.

9. Yaremenko A, Zernitskiy A, Zernitckaia E, Stolyarova A. Laser Modification of the soft tissues in dental implantation zone. 25th EACMFS Congress. Paris, France, 2021.

10. Kelendzheridze YM. The state of microcirculation in the periodontal tissues of the supporting teeth in the orthopedic treatment of a limited defect of the dentition. Dentistry = Stomatologiia. 2007; 1:18-23 (In Russ.).

11. Bogdan Allemann I, Kaufman J. Fractional photothermolysis-an update. Lasers Med Sci. 2010; 25(1):137-44.

12. Belikov AV, Ermolaeva LA, Korzhevsky DE, Sergeeva ES, Semyashkina YV, Antropova MM, et al. Histological examination of the oral mucosa regeneration after fractional diode laser treatment with a wavelength of 980 nm. Proceedings of SPIE. 2018; 10685:1068526.

13. Tavelli L, Nguyen T, Rodriguez MV, Mancini L, Giannobile WV, Barootchi S. Tissue Perfusion and Biomarkers Assessment Following Root Coverage Procedures. J Periodontal Res. 2025.

14. Dias AT, de Menezes CC, Kahn S, Fischer RG, da Silva Figueredo CM, Fernandes GVO. Gingival recession treatment with enamel matrix derivative associated with coronally advanced flap and subepithelial connective tissue graft: a split-mouth randomized controlled clinical trial with molecular evaluation. Clin Oral Investig. 2022;26(2):1453-63.

15. Shomurodov K, Mirkhusanova R. Diagnostic Significance of Peri-Implant Crevicular Fluid Biomarkers: A Narrative Review. Galic Med J. 2025;32 (3):e-GMJ2025-A20.

16. Tavelli L, Barootchi S, Rodriguez MV, Sugai J, Wu DT, Yu N, et al. Characterization of oral biomarkers during early healing at augmented dental implant sites. J Periodont Res. 2025;60:206-14.