PRINCIPLES OF SURGICAL TREATMENT FOR CHRONIC HYPERTROPHIC RHINITIS

Djurayev Jamolbek Abdukakharovich – D.M.Sc., professor
Maxamadaminova Shoira Abduvaliyevna – D.M.Sc., associate professor
Rashidova Madina Zokir qizi – master's student
Tashkent State Medical University (Tashkent, Uzbekistan)

Abstract. *Chronic hypertrophic rhinitis is among the most common disorders of the upper airways and is characterized by hypertrophy of the nasal mucosa and inferior nasal turbinates. The present study was conducted at the Adult ENT Department of the multidisciplinary clinic of Tashkent State Medical University. A total of 115 inpatients who underwent surgical management were included in the analysis. Chronic hypertrophic rhinitis frequently coexisted with chronic sinusitis, allergic rhinitis, deviated nasal septum, adenoid vegetation, chronic tonsillitis, and pharyngitis. The study comparatively evaluated the clinical and functional outcomes of turbinoplasty, electrocoagulation, cryoablation, and electroporation, together with their impact on patient-reported quality of life and mucociliary transport. The comparative analysis showed that all four techniques were clinically useful, but their functional profiles and postoperative recovery patterns differed, enabling identification of the most appropriate surgical option within a differentiated treatment strategy. These findings support individualized surgical selection in chronic hypertrophic rhinitis and underline the importance of mucosa-preserving concepts in contemporary turbinate surgery.*

Key words: *chronic hypertrophic rhinitis, turbinoplasty, electrocoagulation, mucociliary transport.*

SURUNKALI GIPERTROFIK RINITNI JARROHLIK USULIDA DAVOLASH TAMOYILLARI

Djurayev Jamolbek Abdukaxarovich – t.f.d., professor
Makhamadaminova Shoira Abduvaliyevna – t.f.d., dotsent
Rashidova Madina Zokir kizi – magistrant
Toshkent davlat tibbiyot universiteti (Toshkent, O'zbekiston)

Annotatsiya. *Surunkali gipertrofik rinit yuqori nafas yo'llarining keng tarqalgan kasalliklaridan biri bo'lib, burun shilliq qavatining va pastki burun chig'anoqlarining gipertrofiyasi bilan tavsiflanadi. Tadqiqot ishi Toshkent davlat tibbiyot universiteti, ko'p tarmoqli klinikasining kattalar LOR bo'limida o'tkazildi. Bo'limda davolanayotgan va jarrohlik amaliyot o'tkazgan 115 kishini qamrab oldi va chuqur tahlil qilindi. Surunkali gipertrofik rinit ko'pincha surunkali sinusit, allergik rinit, burun to'sig'i qiyshayishi, adenoid vegetatsiya, surunkali tonzillit va faringit bilan bog'liq holda uchraydi. Tadqiqot davomida turbinoplastika, elektrokoagulyatsiya, krioablatsiya va elektroporatsiya usullarining klinik va funksional natijalari, shuningdek ularning bemorlar hayot sifatiga ta'siri baholandi. Olingan natijalar surunkali gipertrofik rinitni davolash uchun eng maqbul jarrohlik usulini aniqlash imkonini beradi.*

Kalit so'zlar: *surunkali gipertrofik rinit, turbinoplastika, elektrokoagulyatsiya, mukotsiliar transport.*

ПРИНЦИПЫ ХИРУРГИЧЕСКОГО ЛЕЧЕНИЯ ХРОНИЧЕСКОГО ГИПЕРТРОФИЧЕСКОГО РИНИТА

Джураев Джамолбек Абдукахарович – д.м.н., профессор
Махамадаминова Шоира Абдувалиевна – д.м.н., доцент
Рашидова Мадина Зокир кизи – магистрант
Ташкентский государственный медицинский университет (Ташкент, Узбекистан)

Аннотация. *Хронический гипертрофический ринит является одним из широко распространённых заболеваний верхних дыхательных путей и характеризуется гипертрофией слизистой оболочки полости носа и нижних носовых раковин. Данное исследование проведено в отделении взрослой ЛОР-патологии многопрофильной клиники Ташкентского государственного медицинского университета. В исследование были включены и всесторонне проанализированы 115 пациентов, находившихся на стационарном лечении и перенёсших хирургическое вмешательство в данном отделении. Хронический гипертрофический ринит нередко сочетается с хроническим синуситом, аллергическим ринитом, искривлением перегородки носа, аденоидными вегетациями, хроническим тонзиллитом и фарингитом. В ходе исследования были оценены клинические и функциональные результаты турбинопластики, электрокоагуляции, криоабляции и электропорации, а также их влияние на качество жизни пациентов. Полученные результаты позволяют определить наиболее оптимальный хирургический метод лечения хронического гипертрофического ринита.*

Ключевые слова: *хронический гипертрофический ринит, турбинопластика, электрокоагуляция, мукоцилиарный транспорт.*

Introduction. Chronic hypertrophic rhinitis is a persistent nasal inflammatory condition in which the inferior turbinate mucosa and, in some patients, the submucosal and osseous framework become enlarged, producing chronic nasal obstruction, impaired nasal breathing, sleep disturbance, hyposmia, and reduced quality of life. In routine ENT practice, the condition often coexists with allergic rhinitis, chronic rhinosinusitis, septal deviation, adenoid hypertrophy, and chronic pharyngo-tonsillar disease, all of which may aggravate nasal obstruction and complicate treatment selection.

Over the last decade, a large body of literature has focused on comparing inferior turbinate reduction techniques. Systematic reviews and meta-analyses have shown that a wide range of surgical methods improve patient-reported nasal obstruction, yet consensus on the single best technique has not been reached. Recent evidence suggests that microdebrider-assisted turbinoplasty and radiofrequency-based approaches provide comparable improvement in symptoms and physiologic airflow, while more destructive techniques may be associated with slower healing or a less favorable functional recovery profile [2,4].

Another important development in recent literature is the renewed interest in function-oriented outcome measures. Beyond symptom scores such as NOSE and SNOT-22, investigators increasingly evaluate endoscopic turbinate size, acoustic or rhinomanometric parameters, and mucociliary clearance [3,12,15]. Recent systematic evidence indicates that turbinate surgery does not inherently impair mucociliary clearance and that mucosa-sparing procedures may even improve mucociliary transport during postoperative recovery.

The growing diversity of minimally invasive and tissue-modulating procedures has broadened the therapeutic armamentarium. In addition to classical turbinoplasty and electrocautery-based methods, cryo-techniques and other energy-based procedures are being explored in chronic rhinitis and inferior turbinate pathology. However, comparative data remain heterogeneous, and treatment choice in real-life settings still depends on local expertise, available equipment, mucosal status, and the extent of structural hypertrophy. Against this background, a comparative single-center analysis remains clinically valuable because it may clarify how different procedures perform when applied within the same institutional workflow [1,5,14].

Aim of the Study. To comparatively evaluate the clinical and functional effectiveness of turbinoplasty, electrocoagulation, cryoablation, and electroporation in the surgical treatment of chronic hypertrophic rhinitis and to determine the most appropriate intervention strategy for patients managed at the Adult ENT Department of Tashkent State Medical University.

Materials and Methods. This study was carried out at the Adult ENT Department of the multidisciplinary clinic of Tashkent State Medical University and included 115 patients with chronic hypertrophic rhinitis who required surgical treatment. The cohort comprised inpatients with persistent nasal obstruction and endoscopically confirmed inferior turbinate hypertrophy that had remained clinically significant despite prior conservative management. The study design was comparative and hospital-based.

Preoperative evaluation included clinical history taking, anterior rhinoscopy, rigid nasal endoscopy, assessment of associated sinonasal pathology, and functional analysis of nasal breathing. Particular attention was paid to concomitant chronic sinusitis, allergic rhinitis, septal deviation, adenoid vegetation, chronic tonsillitis, and pharyngitis, because these conditions can influence both symptoms and treatment selection. Functional assessment was centered on nasal obstruction severity, endoscopic turbinate configuration, and mucociliary transport, the latter serving as an important indicator of preservation of physiologic nasal function.

Patients underwent one of four surgical interventions used in routine departmental practice: turbinoplasty, electrocoagulation, cryoablation, or electroporation. The choice of procedure was based on the degree and pattern of turbinate hypertrophy, the presumed mucosal versus submucosal predominance of the process, functional status of the mucosa, and the treating surgeon's clinical judgment. In all cases, the operative goal was to achieve a stable reduction of turbinate volume while preserving as much functional mucosa as possible.

Postoperative assessment focused on symptom regression, endoscopic healing, restoration of nasal airflow, recovery of mucociliary transport, and patient-reported quality of life. Comparative evaluation was performed across the four treatment categories. Because only the study summary rather than the full source dataset was available at the time of drafting this manuscript, the present text is formulated as a publication-style article draft and should be harmonized with the original statistical tables before submission [6,7,13].

Results. The analysis of the 115 operated patients confirmed that chronic hypertrophic rhinitis in the present cohort was commonly associated with other chronic upper airway disorders, most notably chronic sinusitis, allergic rhinitis, septal deviation, adenoid vegetation, chronic tonsillitis, and pharyngitis. This multimorbid background supports the concept that hypertrophic turbinate disease should be interpreted as part of a broader functional and inflammatory sinonasal complex rather than as an isolated structural abnormality.

All four studied interventions-turbinoplasty, electrocoagulation, cryoablation, and electroporation-were associated with postoperative improvement in nasal obstruction and overall clinical status. However, the comparative analysis indicated that the procedures differed in their functional profile, particularly with regard to mucosal preservation, early postoperative recovery, and restoration of physiologic nasal function. Turbinoplasty demonstrated the most balanced effect when both decongestion and preservation of mucociliary transport were considered. Electrocoagulation was effective in reducing hypertrophic tissue, but the recovery pattern suggested a greater dependence on postoperative mucosal repair. Cryoablation provided favorable local tolerability and satisfactory symptom control, while electroporation appeared useful as a tissue-sparing option in selected cases.

Procedure	Primary therapeutic target	Expected strengths	Potential limitations
Turbinoplasty	Volume reduction with mucosal preservation	Durable airway improvement; favorable functional profile; better preservation of mucociliary transport	Technically more demanding; may require longer learning curve
Electrocoagulation	Submucosal tissue shrinkage by thermal effect	Widely available; technically straightforward; effective decongestion	Greater thermal injury potential; crusting and slower mucosal recovery may occur
Cryoablation	Controlled tissue modulation with low thermal burden	Good tolerability; favorable symptom relief; limited bleeding	Long-term evidence in classic hypertrophic rhinitis remains less extensive
Electroporation	Tissue-directed bioelectrical modulation	Potentially tissue-sparing; promising in selected patients	Comparative evidence remains limited; requires further validation

Assessment of quality of life showed an overall favorable trend after surgery across all groups, indicating that relief of chronic nasal obstruction translated into meaningful functional benefit for patients. The comparative profile of the cohort suggests that procedures preserving mucosal integrity are more consistent with contemporary function-oriented management principles than purely destructive volume-reduction techniques.

Taken together, the study findings support the use of differentiated surgical decision-making in chronic hypertrophic rhinitis [8,10,11]. Rather than applying one method universally, the results favor matching the operative technique to the structural and functional characteristics of the inferior turbinate in each patient.

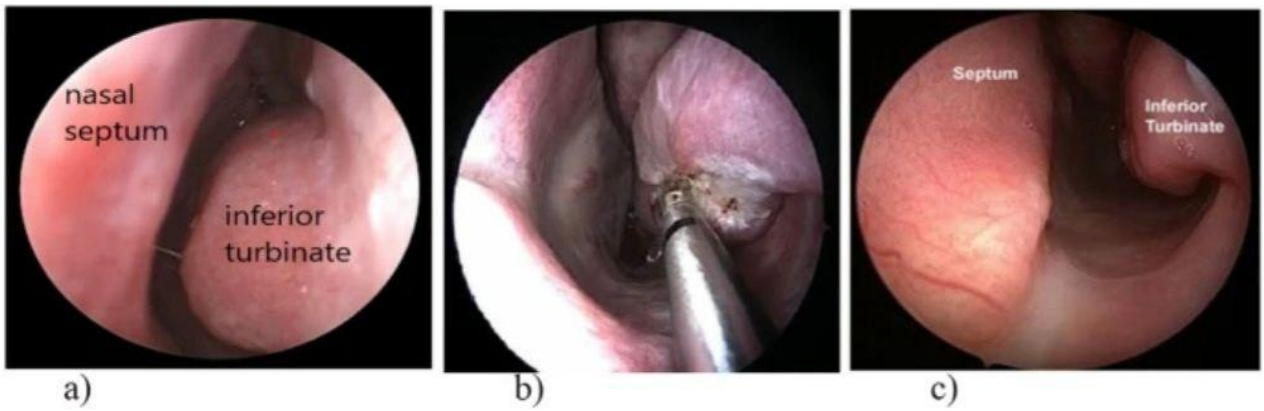

Endoscopic views of left nasal cavity in coblation surgery. a Pre-operative hypertrophied left inferior turbinate. b Intraoperative coblation blade inside left inferior turbinate. c Postoperative picture of left inferior turbinate after 3 months of removal of its submucosal layer by coblation. Computed tomographic scan of bilateral nasal cavities. a preoperative view of hypertrophied inferior turbinate, b) three months postoperative view of operated inferior turbinate by traditional partial inferior turbinectomy surgery [7].

Discussion. The findings of the present study are broadly consistent with modern literature on inferior turbinate surgery. Recent systematic reviews confirm that most inferior turbinate reduction procedures produce meaningful relief of nasal obstruction, but also emphasize that the best current evidence favors mucosa-sparing concepts. The present

study also aligns with literature emphasizing the importance of mucociliary preservation. A 2024 systematic review and meta-analysis found that turbinate surgery does not compromise mucociliary clearance overall, and that mucosa-sparing procedures may even improve mucociliary transport during the early postoperative period [12]. This perspective strengthens the relevance of mucociliary transport as a core outcome measure in chronic hypertrophic rhinitis and supports the clinical preference for techniques that minimize mucosal destruction.

Comparative studies performed over the last decade further support differentiated technique selection. A prospective randomized clinical study by Akagün et al. showed that both radiofrequency thermal ablation and microdebrider-assisted turbinoplasty are effective for inferior turbinate hypertrophy, but emphasized that the final choice should take tissue healing, volume reduction, and mucociliary activity into account. Similar comparative work demonstrated favorable results for both microdebrider-assisted turbinoplasty and coblation-based methods, while more recent pilot data comparing submucosal cauterization and turbinoplasty again stressed the balance between efficacy, early postoperative comfort, and cost or technical simplicity.

Cryoablation deserves particular attention because it reflects the broader transition toward function-oriented treatment in chronic rhinitis. Although most recent cryotherapy studies concern chronic rhinitis more generally rather than classic chronic hypertrophic rhinitis alone, a 2024 systematic review and meta-analysis showed consistent improvement in symptom and quality-of-life scores after cryotherapy. This supports the rationale for including cryo-based methods in comparative practice, particularly when low thermal burden and postoperative tolerability are desired.

Overall, the present cohort supports a pragmatic but modern surgical principle: no single intervention is universally optimal for all patients with chronic hypertrophic rhinitis. The most appropriate procedure depends on the structural pattern of hypertrophy, the need for mucosal preservation, the degree of associated inflammatory disease, and the expected functional recovery. The present study therefore contributes practical comparative evidence from a single tertiary ENT department and supports personalized surgical selection.

Conclusion. The comparative evaluation performed in 115 surgically treated patients demonstrated that turbinoplasty, electrocoagulation, cryoablation, and electroporation are all clinically useful methods for chronic hypertrophic rhinitis, but they differ in their functional profile and postoperative recovery pattern. The study supports individualized surgical planning based on the degree of inferior turbinate hypertrophy, the need for mucosal preservation, and the broader sinonasal background of the patient. Among the analyzed approaches, mucosa-oriented surgery appeared to provide the most favorable balance between symptom relief and preservation of physiologic nasal function. The findings underline the importance of integrating endoscopic, functional, and quality-of-life assessment into the choice of surgical technique for chronic hypertrophic rhinitis.

REFERENCES

1. Akagün F, İmamoğlu M, Cobanoğlu HB, Ural A. Comparison of Radiofrequency Thermal Ablation and Microdebrider-Assisted Turbinoplasty in Inferior Turbinate Hypertrophy: A Prospective, Randomized, and Clinical Study. Turk Arch Otorhinolaryngol. 2016;54(3):118-123.

2. Türk B, Korkut AY, Cobanoğlu BÜ, et al. Results of Radiofrequency Ablation of Inferior Turbinate Hypertrophy in Patients with Allergic and Non-Allergic Rhinitis. Sisli Etfal Hastan Tip Bul. 2018; 52(4):296-300.

3. Gül Z, Aydoğdu D, Ülkü ÇH. Comparison of Radiofrequency and Microdebrider-Assisted Turbinoplasty for Treatment of Isolated Inferior Turbinate Hypertrophy. Eur J Rhinol Allergy. 2019;2(2):51-56.

4. Singh S, Ramli RR, Wan Mohammad Z, Abdullah B. Coblation versus microdebrider-assisted turbinoplasty for endoscopic inferior turbinates reduction. Auris Nasus Larynx. 2020;47(4):593-601.

5. Abdullah B, Singh S. Surgical Interventions for Inferior Turbinate Hypertrophy: A Comprehensive Review of Current Techniques and Technologies. Int J Environ Res Public Health. 2021;18(7): 3441.

6. Harju T, Numminen J. The effect of inferior turbinate surgery on nasal symptoms and inferior turbinate contractility. Am J Otolaryngol. 2021;42 (1):102778.

7. Kanesan N, Prepageran N, Abdullah B. Microdebrider-assisted inferior turbinoplasty versus other surgical techniques for inferior turbinate hypertrophy: a systematic review and meta-analysis. Eur Arch Otorhinolaryngol. 2022;279(12):5401-5417.

8. Zhang K, Pipaliya RM, Miglani A, Nguyen SA, Schlosser RJ. Systematic Review of Surgical Interventions for Inferior Turbinate Hypertrophy. Am J Rhinol Allergy. 2023;37(2):178-191.

9. Patil V, Indumathi S, Patil R, Latadevi HT, Sorganvi V. A comparative study between turbinoplasty and submucosal cautery for surgical management of inferior turbinate hypertrophy and correlation with improvement in nasal obstruction. Al Ameen J Med Sci. 2023;16(1):74-79.

10. Smith DH, Sowerby LJ, Rotenberg B. Surgical Management of Inferior Turbinate Hypertrophy in the Era of Widespread Communicable Disease. Otolaryngol Head Neck Surg. 2023;168(3):505-512.

11. Alanazi F, Aljuaid A, et al. Safety and efficacy of cryotherapy on chronic rhinitis: a systematic review and meta-analysis. Am J Otolaryngol. 2024;45 (5):104278.

12. Calvo-Henríquez C, et al. Effect of turbinate surgery on mucociliary clearance: a systematic review and meta-analysis. Acta Otorrinolaringol Esp (Engl Ed). 2024;75(4):255-264.

13. Ali AR, et al. Comparative study between surgical partial inferior nasal turbinectomy and coblation-assisted inferior turbinate reduction in cases of inferior nasal turbinate hypertrophy. Egypt J Otolaryngol. 2024;40:1-9.

14. Kazemi T, et al. Comparing sinonasal quality of life in pediatric nasal obstruction: inferior turbinate cauterization vs turbinoplasty – a pilot study. Int J Pediatr Otorhinolaryngol. 2024;185:112076.

15. Rehman A, Iftikhar T, Hussain S, et al. Microdebrider-assisted turbinoplasty versus radiofrequency ablation for inferior turbinate hypertrophy: a systematic review and meta-analysis of randomized controlled trials. Egypt J Otolaryngol. 2025;41:221.